



PATIENT PRESENTING CLINICAL SIGNS

- Mawby Lavin
- Chronic nasal congestion since November, intermittent symptoms of otitis externa in that time as well.
 - Prednisolone taper did not seem to have any change on clinical signs.
- SPECIES**
- Veraflox seemed to help somewhat with the nasal discharge.

Feline

COMPUTED TOMOGRAPHIC STUDY OF THE HEAD

BREED Plain and post contrast studies are available for review.

DMH COMPUTED TOMOGRAPHIC FINDINGS

SEX The CT study reveals a large ill-defined soft tissue attenuating mass measuring ~ 5 by 3 by 1 cm occupying the nasopharynx and causing obstruction of the upper airways. The mass presents heterogeneous contrast enhancement; lesion margins are ill-defined and blend into the surrounding soft tissue.

MN

Severe bilateral retropharyngeal lymph node enlargement with heterogeneous contrast enhancement is seen.

AGE

13yr There is fluid accumulating within the nasal cavities and tympanic bullae, likely secondary to obstruction of the normal drainage pathways.

INTERPRETED BY Resorptive changes are noted in multiple dental roots.

Nele Eley (Ondreka),
DVM Dr. med. vet.,
DipECVDI

COMPUTED TOMOGRAPHIC DIAGNOSIS

- Large obstructive nasopharyngeal mass with aggressive biological behavior
- Severe bilateral retropharyngeal lymphadenomegaly
- Mass effect causing nasal congestion and effusive otitis media bilaterally

HOSPITAL NAME

Wilson Veterinary
Hospital

INTERPRETATION OF FINDINGS & FURTHER RECOMMENDATIONS

The CT study reveals a large soft tissue mass within the nasopharynx causing upper airway obstruction. The CT findings are consistent with aggressive biological behavior. Nasopharyngeal carcinoma is a primary differential diagnosis. Lymphoma, fibrosarcoma and melanoma are potential but yet less likely differential diagnoses.

REFERRING VET

Dr Willauer

The findings of the lymph nodes are highly suggestive for metastatic involvement or lymphomatous infiltrate.

INVOICE

23988

FNA biopsy of the nasopharyngeal mass and enlarged lymph nodes could be performed for further definition.

DATE

02/25/2026



PATIENT

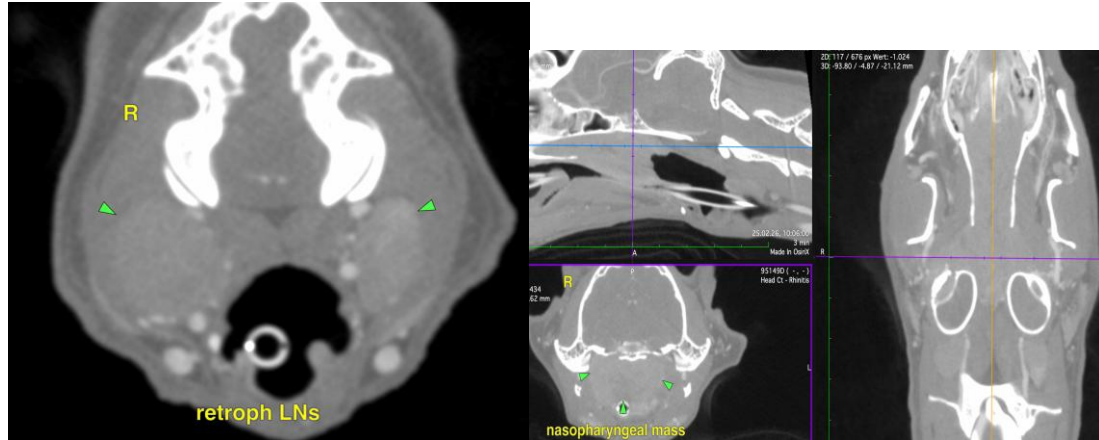
Mawby Lavin

SPECIES

Feline

BREED

DMH



SEX

MN

The information and recommendations provided are based on the images presented by the referring veterinarian. No evaluation can be communicated regarding pathology that was not visible in the image/video clips provided.

AGE

13yr

Thank you for this referral. If the clinical or image interpretation does not parallel your findings or if I can be of any further assistance please contact me.

INTERPRETED BY

Nele Eley (Ondreka),
DVM Dr. med. vet.,
DipECVDI

Nele Eley (Ondreka), DVM, Dr. med. vet., DipECVDI
European Specialist in Veterinary Diagnostic Imaging, Cert. Radiology,
Senior lecturer University of Giessen/Germany, Veterinary Faculty, Department of Radiology.
info@sonopath.com

HOSPITAL NAME

Wilson Veterinary
Hospital

REFERRING VET

Dr Willauer

INVOICE

23988

DATE

02/25/2026